

See discussions, stats, and author profiles for this publication at: <https://www.researchgate.net/publication/282133184>

Usher Syndrome: Case Reports of Two Siblings

Article in *Optometry and Vision Science* · June 2015

READS

15

4 authors:



Raman Prasad Sah

Institute of Medicine

7 PUBLICATIONS 2 CITATIONS

SEE PROFILE



Pragati Gautam

Tribhuvan University

8 PUBLICATIONS 3 CITATIONS

SEE PROFILE



Jyoti Baba Shrestha

Institute of Medicine

16 PUBLICATIONS 52 CITATIONS

SEE PROFILE



Mahesh Raj Joshi

Glasgow Caledonian University

13 PUBLICATIONS 39 CITATIONS

SEE PROFILE

Article ▶ Usher Syndrome: Case Reports of Two Siblings

Raman Prasad Sah, B.Optom, B.P. Koirala Lions Centre for Ophthalmic Studies, Maharajgunj, Kathmandu, Nepal

Pragati Gautam, MD, B.P. Koirala Lions Centre for Ophthalmic Studies, Maharajgunj, Kathmandu, Nepal

Jyoti Baba Shrestha, MD, B.P. Koirala Lions Centre for Ophthalmic Studies, Maharajgunj, Kathmandu, Nepal

Mahesh Raj Joshi, M.Optom, B.P. Koirala Lions Centre for Ophthalmic Studies, Maharajgunj, Kathmandu, Nepal

ABSTRACT

Background: Usher syndrome is a rare autosomal recessive disorder characterized by congenital sensory neural deafness and progressive visual loss secondary to retinitis pigmentosa. There are three different types of Usher syndrome. Retinitis pigmentosa is the main ophthalmic manifestation shared by all three. Differences in auditory and vestibular function are the distinguishing feature.

Case Reports: Two brothers, 13 and 16 years of age, presented with chief complaints of progressive diminution of vision in both eyes, especially at night. They underwent a detailed evaluation which included dilated fundus examination, cycloplegic refraction, multifocal electroretinogram (mfERG), optical coherence tomography, visual evoked potential, and Goldmann perimetry. The evaluation revealed best corrected visual acuity of 6/12 and 6/9 in each case despite the presence of bony spicules and abolished mfERG amplitudes. The clinical findings supported the diagnosis of Usher syndrome Type I.

Discussion: Early detection and intervention will help preserve residual vision in these cases.

Keywords: multifocal electroretinogram, retinitis pigmentosa, sensory neural deafness, Usher syndrome, visual field

Introduction

Usher syndrome is a disorder characterized by retinitis pigmentosa (RP) and congenital sensorineural hearing loss. It is a rare disorder with an incidence of 3 to 4.4 per 100,000 people.¹ However, it is the most common cause of combined hearing and visual loss with a prevalence of three to six percent.² The disorder is transmitted through an autosomal recessive inheritance.

There are three different variants of Usher syndrome: Types I, II, and III.^{3,4} Type I is the most severe form of the disorder with profound hearing loss and onset from birth accompanied by difficulty with night vision in the first decade of life. Type II is characterized by moderate hearing loss with later onset of night vision problems. Type III is accompanied by progressive hearing and night vision loss with onset in the late teenage years. Although some authors have reported that Types I and II are equally frequent, several studies have found that Type II is two or three times more frequent than Type I.^{1,5} Here we report the clinical ophthalmic presentation of two siblings with Usher syndrome Type I with typical congenital hearing loss and night vision problems secondary to retinitis pigmentosa.

Case Reports

Two brothers, ages 13 and 16, presented with chief complaints of progressive diminution of vision in both eyes, especially at night. Their mother gave a history of normal

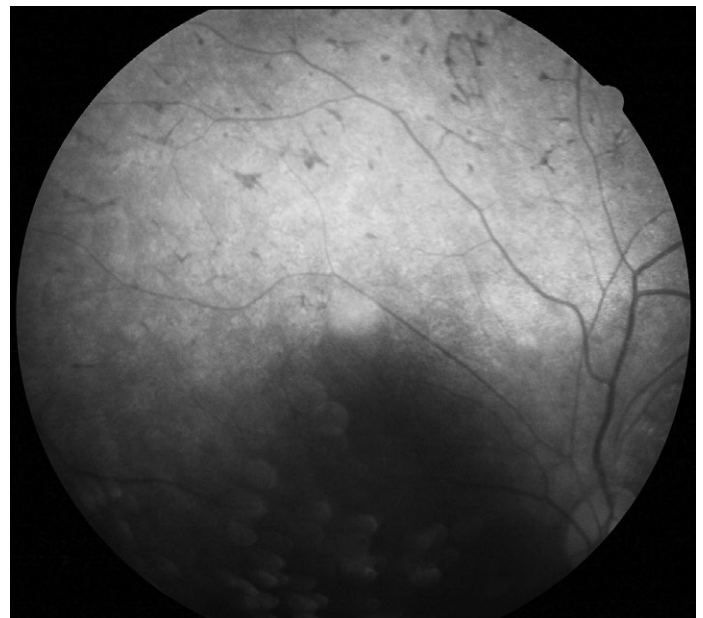


Figure 1: Case 1 fundus photo

full term birth in a hospital with hearing loss and inability to speak since childhood. A third sibling had no history of any visual or auditory problems. There was also no history of any similar condition in either of their parents or any other close family members. Both of these children underwent detailed ophthalmic examination, which is discussed below.

Table 1: ERG amplitudes of Case I and Case II. [OD/OS is conventional abbreviation for right eye/left eye and would be easier to understand, as RE is a common abbreviation for refractive error]

Rings	Amplitude P1(nV/deg ²)				Amplitude N1 (nV/deg ²)			
	Case I		Case II		Case I		Case II	
Eye	OD	OS	OD	OS	OD	OS	OD	OS
Ring 1	56.8	17.3	22.8	24.50	32.12	22.25	0.17	15
Ring 2	32.2	31.5	0	0	7.12	11.2	2.9	0.73
Ring 3	5.05	9.9	0	3.62	2.6	14.53	2.23	3.48
Ring 4	7.48	1.15	7.51	2.05	1.59	0.19	0.36	1.22
Ring 5	3.17	2.82	1.9	0.76	0.11	2.57	0.6	0.66

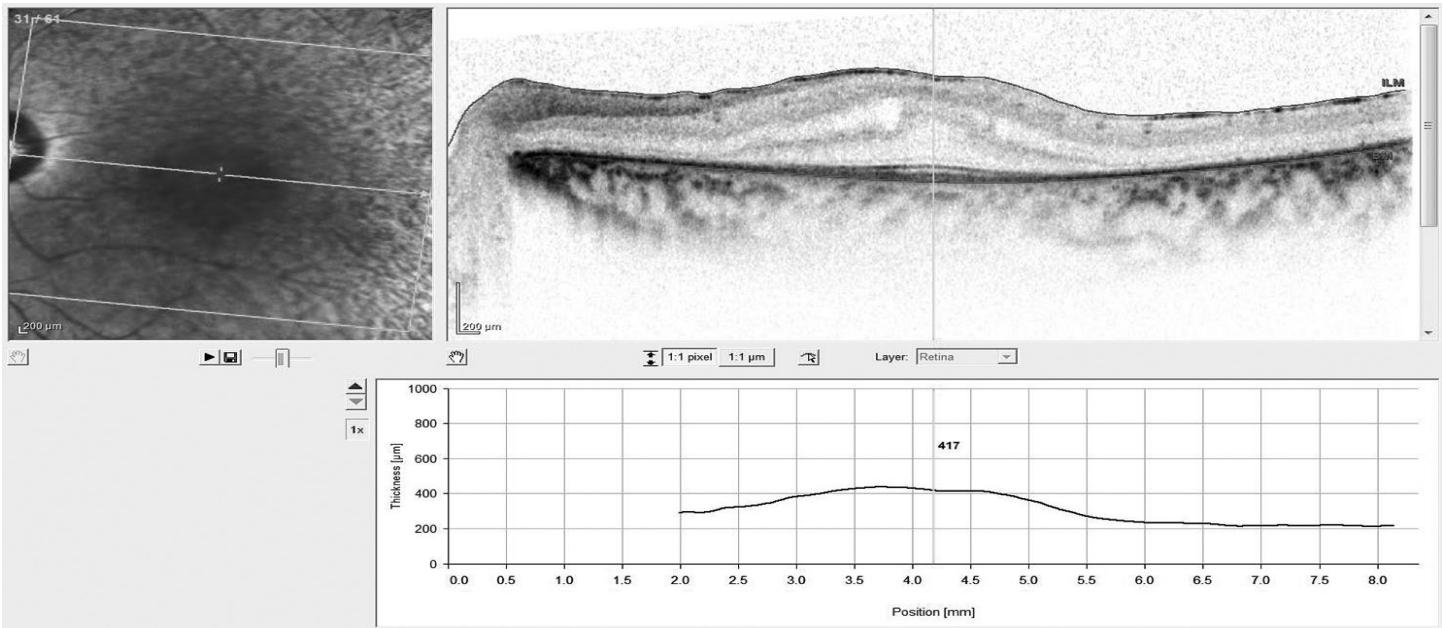


Figure 2: Case 1 OCT

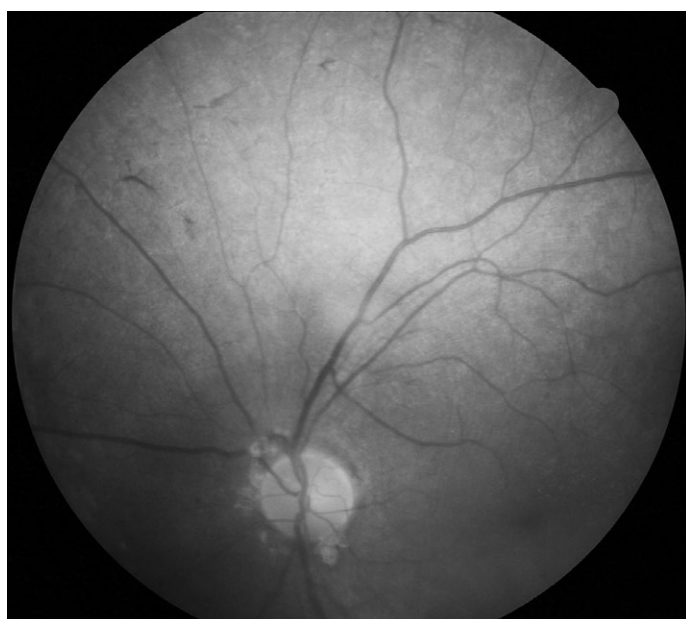

Figure 3: Case 2 fundus photo

Case I

Unaided visual acuity (VA) was 6/36 in both eyes. All anterior segment findings were within normal limits. Pupils were normal with no afferent pupillary defect. Fundus examination revealed multiple bony spicules in the retinal periphery and marked arteriolar attenuation in both eyes (Figure 1). Cycloplegic refraction revealed refractive correction of +4.00-2.00x180 OD and +4.50 DS OS with a monocular visual acuity of 6/12 in each eye. Goldmann perimetry revealed peripheral visual field constriction with relative defects in the paracentral region in both eyes. Multifocal electroretinogram (mfERG) showed abolished P1 and N1 peaks at all rings (Table 1). Optical coherence tomography (OCT) demonstrated average macular thicknesses of 446 μm in the right eye and 410 μm in the left with normal retinal nerve fiber layer (RNFL) thickness in all quadrants (Figure 2). Upon consultation with an ear, nose, and throat specialist, audiometry reported a response at >100 db in the right ear and 98 db in the left, indicating profound hearing loss in both ears.

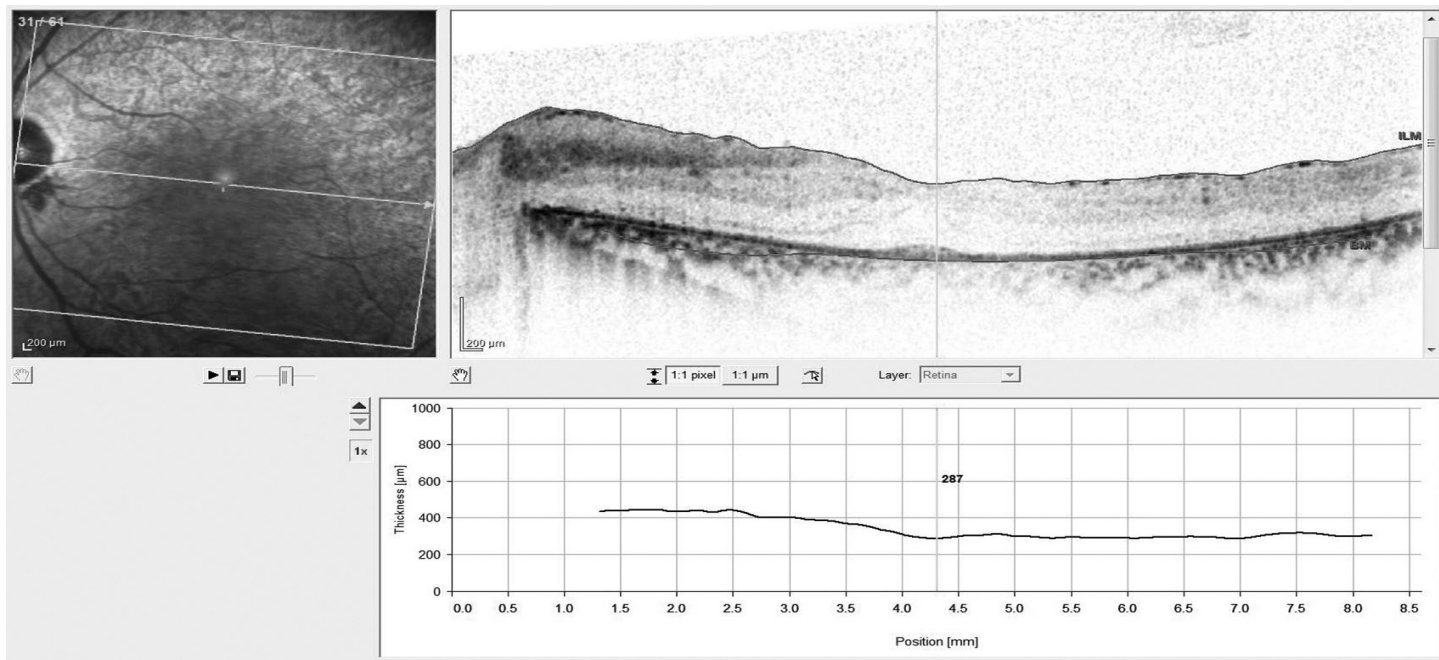


Figure 4: Case 2 OCT

Case II

Unaided VA was 6/18 in both eyes. All anterior segment findings were within normal limits. Pupils were normal with no afferent pupillary defect. Fundus examination revealed multiple bony spicules in the retinal periphery with marked arteriolar attenuation in both eyes (Figure 3). Cycloplegic refraction revealed refractive correction of +2.00-1.00x90 with a VA of 6/9 in both eyes. Goldmann perimetry demonstrated peripheral constriction of the visual field with relative defects in the paracentral region in both eyes. Multifocal electroretinogram showed abolished P1 and N1 peaks at all rings. OCT showed average macular thicknesses to be 337 µm in the right eye and 317 µm in the left; RNFL was within normal limits in all quadrants except for the nasal region (Figure 4). Audiometry findings revealed profound hearing loss in both ears with responses at 94 db and 104 db for right and left ears, respectively.

Discussion

Usher syndrome is characterized by three clinical subtypes. Although differences in auditory and vestibular function are the distinguishing features, RP is the main ophthalmic manifestation shared by all three types. Concerning vestibular pathology, the clinical signs observed are delays in motor acquisitions, with affected children experiencing frequent falls and who are late to sit and stand. Vestibular examination can provide additional information, but it does not by itself allow a positive diagnosis, because vestibular functions can be affected in patients with congenital deafness, especially in inner ear malformation and cyto-megalovirus infection. On the other hand, a normal vestibular function does not eliminate the diagnosis.⁶ The classification based on clinical findings,

including the onset of hearing loss and RP, is widely used to determine the various types of Usher syndrome.^{3,4}

In the cases described, the auditory loss was congenital, and each child had difficulty with night vision beginning in early childhood. Therefore, these cases would be categorized as Usher type I. Genetic testing has determined nine different genes⁴ which are responsible for Usher syndrome with an autosomal recessive inheritance pattern. In the family reported here, one of the siblings was unaffected, which supports the well-established theory of an autosomal recessive inheritance pattern.

On clinical evaluation, the best corrected VA was 6/9 and 6/12 in each case. Though extensive RP has been reported in cases of Usher syndrome, central visual acuity is reported to be preserved until late in life, typically until the 5th to 7th decade with visual acuity of 6/60.⁷ Both cases had hypermetropic refractive correction which could be due to the shorter than average axial lengths. Goldmann visual field testing revealed peripheral constriction accompanied by relative paracentral scotoma in both cases. This is in accordance with reported visual field defects seen in RP.

The retinal findings showed marked pigmentary changes in mid peripheral and peripheral retina with an absent foveal reflex. The OCT confirmed the presence of macular edema in both cases. Various studies have reported the presence of macular edema and cystoid macular edema in cases of RP and Usher syndrome.^{8,9}

Electrophysiologic tests such as ERG have been reported to detect even sub-clinical cases of RP.¹⁰ Multifocal ERG, which allows a high-resolution mapping of the macular area of the retina, has been described as an early predictor of the disease.¹¹ In our cases, the mfERG showed marked reduction of P1 and

N1 amplitudes in central as well as peripheral rings compared to normal subjects. For each component of the mfERG, P1 generates from the inner retinal layer, including bipolar and Muller cells, and N1 generates from the outer retinal layer. Hence, reduction of both these waves signifies impaired retinal function as a whole.^{12,13}

Usher syndrome affects both the auditory and visual systems and renders the patient functionally handicapped. It is important for children suffering from Usher syndrome to receive early diagnosis, which aids in re-adjustments on the part of the patients and parents for proper functioning in society.¹⁴ Patients with Usher syndrome experience multiple visual disabilities, including reduced contrast sensitivity, poor dark adaptation, glare, and night blindness. These disabilities may lead to difficulties with walking, recognizing objects, and other activities of daily living. Hence, optometrists play an important role in the provision of proper refractive correction and low vision services to enhance their visual capability as much as possible. Early and appropriate refractive correction helps to prevent amblyopia. For night blindness and dark-adaptation difficulties, a simple penlight is very useful for searching in dark cabinets or for mobility at night. Near visual aids such as hand-held lighted magnifiers and closed-circuit televisions are helpful for reading and writing. Patients with RP walk more slowly and are more likely to suffer a fall, especially in unfamiliar surroundings; hence, orientation and mobility services such as guide dogs and cane sticks are often helpful.

Studies also suggest that early cochlear implants and speech therapy can strengthen auditory and speech potentials.¹⁵ Appropriate genetic counseling to the parents can lead to awareness regarding the disorder and help to reduce its occurrence in future. Researchers are currently trying to identify all of the genes that cause Usher syndrome and to determine the function of those genes, leading to early diagnosis and improved genetic counseling, which may eventually expand treatment options.

Conclusion

Usher syndrome leads the patient to experience multiple visual, auditory, and speech disabilities, rendering them functionally handicapped. Early detection and appropriate intervention will help preserve the residual vision and strengthen auditory and speech potentials in these cases. The role of the optometrist in these cases includes diagnosis, treatment, and interaction amongst other professionals on the treatment team.

References

1. Rosenberg T, Haim M, Hauch A-M, Parving A. The prevalence of Usher syndrome and other retinal dystrophy-hearing impairment associations. *Clin Genet* 1997;51:314-21.
2. Boughman JA, Vernon M, Shaver KA. Usher syndrome: definition and estimate of prevalence from two high-risk populations. *J Chronic Dis* 1983;36:595-603.
3. Kremer H, van Wijk E, Marker T, Wolfrum U, et al. Usher syndrome: molecular links of pathogenesis, proteins and pathways. *Hum Mol Genet* 2006;15 Spec No 2: R262-70.
4. Yan D, Liu XZ. Genetics and pathological mechanisms of Usher syndrome. *J Hum Genet* 2010;55:327-35.
5. Spandau UH, Rohrschneider K. Prevalence and geographical distribution of Usher syndrome. *Graefes Arch Clin Exp Ophthalmol* 2002;240:495-8.
6. Loundon N, Marlin S, Busquet D, Denoyelle F, et al. Usher syndrome and cochlear implantation. *Otol Neurotol* 2003;24:216-21.
7. Edwards A, Fishman GA, Anderson RJ, Grover S, et al. Visual acuity and visual field impairment in Usher syndrome. *Arch Ophthalmol* 1998;116:165-8.
8. Ffytche TJ. Cystoid maculopathy in retinitis pigmentosa. *Trans Ophthalmol Soc UK* 1972;92:265-83.
9. Hajali M, Fishman GA. The prevalence of cystoid macular oedema on optical coherence tomography in retinitis pigmentosa patients without cystic changes on fundus examination. *Eye (Lond)* 2009;23:915-9.
10. Flores-Guevara R, Renault F, Loundon N, Marlin S, et al. Usher syndrome type 1: Early detection of electroretinographic changes. *Eur J Paediatr Neurol* 2009;13:505-7.
11. Janaky M, Palfy A, Deak A, Szilagy M, et al. Multifocal ERG reveals several patterns of cone degeneration in Retinitis pigmentosa with concentric narrowing of the visual field. *Invest Ophthalmol Vis Sci* 2007;48:383-9.
12. Hood DC, Seiple W, Holopigian K, Greenstein V. A comparison of the components of the multifocal and full-field ERGs. *Vis Neurosci* 1997;14:533-44.
13. Hood DC, Greenstein V, Frishman L, et al. Identifying innerretinal contributions to the human multifocal ERG. *Vision Res* 1999;39:2285-91.
14. Young NM, Mets MB, Hain TC. Early diagnosis of Usher syndrome in infants and children. *Am J Otol* 1996;17:30-4.
15. Liu XZ, Angeli SI, Rajput K, Yan D, et al. Cochlear implantation in individuals with Usher type 1 syndrome. *Int J Pediatr Otorhinolaryngol* 2008;72:841-7.

Correspondence regarding this article should be emailed to Raman Prasad Sah at raman@iom.edu.np. All statements are the authors' personal opinions and may not reflect the opinions of the representative organizations, ACBO or OEPP, Optometry & Visual Performance, or any institution or organization with which the authors may be affiliated. Permission to use reprints of this article must be obtained from the editor. Copyright 2015 Optometric Extension Program Foundation. Online access is available at www.acbo.org.au, www.oepf.org, and www.ovpjournal.org.

Sah RP, Gautam P, Shrestha JB, Joshi MR. Usher syndrome: case reports of two siblings. *Optom Vis Perf* 2015;3(3):174-7.

The online version of this article contains digital enhancements.